

## Pathogenetic role of *Staphylococcus aureus* in purulent keratoconjunctivitis in cats

S. N. Maslikov, D. D. Bely, V. V. Samoiliuk, V. V. Vakulik, T. L. Spitsyna

Dnipro State Agrarian and Economic University, Dnipro, Ukraine

### Article info

Received 12.10.2019

Received in revised form  
08.11.2019

Accepted 09.11.2019

Dnipro State Agrarian  
and Economic University,  
S. Efremov st., 25,  
Dnipro, 49600, Ukraine.  
Tel.: +38-097-252-62-73.  
E-mail:  
maslikovs.62@ukr.net

Maslikov, S. N., Bely, D. D., Samoiliuk, V. V., Vakulik, V. V., & Spitsyna, T. L. (2019). Pathogenetic role of *Staphylococcus aureus* in purulent keratoconjunctivitis in cats. *Regulatory Mechanisms in Biosystems*, 10(4), 507–512. doi:10.15421/021974

The research was carried out in the Department of Surgery and Obstetrics of Agricultural Animals of Dnipro State Agrarian and Economic University on clinically healthy outbred cats of different ages with purulent keratoconjunctivitis. Hematological, biochemical and immunological parameters were determined in the animals, and microbiological and virological research was conducted on them. According to the data obtained, more than half of cases of ophthalmopathy in cats were conjunctivitis and keratoconjunctivitis, and they were more often registered in the cold season. The main causes of eye diseases in the cats were mechanical injuries, coccidial and chlamydial infection, allergy and development of disease against the background of primary lesions of the ears and paranasal sinuses. Among the detected microorganisms, the vast majority (81.9%) were staphylococci, including *S. albus*, *S. aureus* and *S. epidermidis*. All types of microorganisms except O-forms of *Bacillus* sp. exhibited high and medium sensitivity to antibiotics. Immunoblotting revealed polypeptides that responded to specific *S. aureus* antigens in samples of conjunctiva, cornea, intraocular fluid, and blood of cats suffering from purulent (staphylococcal) keratoconjunctivitis. The highest antigen concentration was detected in the cornea and conjunctiva. In the absence of expressive shifts of the investigated hematological and biochemical parameters, the dynamics of immunological markers were shown by a significant increase in the content of immunoglobulins and circulating immune complexes, as well as by a distinct activation of the complement system by the classical route. The results showed a clear gradual activation of phagocytosis, namely: the number of phagocytic neutrophils increased, reaching its maximum value by the seventh day of development of purulent keratoconjunctivitis. The phagocytic index in the first three days of observation tended to decrease, and by the seventh day it had already significantly exceeded the initial value. Despite the ambiguous dynamics of the phagocytic index, in the course of the development of the inflammatory process in the blood of sick cats, we observed a clear increase in the index of complete phagocytosis. Thus, the development of purulent keratoconjunctivitis in cats occurs against the background of clear cellular and humoral responses to the infectious agent.

Keywords: cats; ophthalmopathy; diagnostics; microorganisms; immunoblotting.

### Introduction

Conjunctivitis in cats is characterized by a multitude of possible etiological factors, including the herpes virus (FHV), *Chlamydomydia felis*, mycoplasma and aerobic bacteria. Among the latter, the most common species are *Staphylococcus*, *Streptococcus* and *Micrococcus* (Hartmann et al., 2010). In particular, according to Büttner et al. (2019), microorganisms that are the cause of conjunctivitis were isolated in 40.8% of clinically healthy cats. Gram-positive bacteria accounted for 71%, gram-negative bacteria – 26%, fungi – 3%, with the highest prevalence being for *S. felis* (19.8%) and *M. osloensis* (5.8%). For many years, *S. aureus* was thought to occur only in humans. Recent studies indicate its prevalence in both domestic and farm animals, which can be a reservoir of infection against the background of proven pathways for transmission in humans (Bierowiec et al., 2014; Köck et al., 2014). *S. aureus* in both human and veterinary medicine is recognized as a significant pathogenetic factor in the development of the disease. Given the isolation of *S. aureus* isolates at 17.5% and methicillin-resistant (MRSA) in 6.5% of clinically healthy animals, Bierowiec et al. (2016), the risk factors for the infection include the work of the owners in the field of health care, work in veterinary medicine and the fact that the cats were treated with antibiotics during the year. Numerous reports indicate that cats may play a role in the transmission of methicillin-resistant *S. aureus* (MRSA) to humans, but the lack of data on its prevalence in animals makes it impossible to study this process in detail (Bramble et al., 2011). In this case, pets and humans are susceptible to infection with both *S. aureus* and MRSA (Kottler et al., 2010).

Comparison of genetic markers indicates the widespread distribution of identical *S. aureus* strains among animals (36.3%) and veterinary staff (38.9%) with the presence of PVL-positive clone home companions, which are a possible source of transmission to humans (Drougka et al., 2016). *S. aureus* is capable of infecting the lacrimal duct, eyelids, conjunctiva, cornea, anterior and posterior chambers of the eye, as well as the vitreous, causing loss of vision or even blindness (O'Callaghan, 2018). Importantly, there is no difference in the species composition of the eye microflora between clinically healthy animals and patients with conjunctivitis, although in the latter case *S. epidermidis* and *S. aureus* were most commonly isolated (Kielbowicz et al., 2015). A considerable number of reports have been devoted to identifying bacterial associations of the conjunctival sac. In particular, Espinola & Lilenbaum (1996) emphasize the importance of the species *S. felis*, although they indicate a significant prevalence of *S. epidermidis* (45.7%), *S. simulans* (23.9%), *S. auricularis* (17%) and *S. saprophyticus* (6.5%). Aftab et al. (2019) note also the high presence in the conjunctival sac of *S. pyogenes* (18.9%) and *Escherichia coli* (11.5%). A significant increase in the prevalence among cats resistant to antibacterial agents of pathogenic *Staphylococcus* species, in particular *S. aureus*, has been demonstrated (Lane et al., 2018). Insufficient study of pathogenesis of conjunctivitis in cats is confirmed by the results of modern observations, in which, based on the analysis of the 16S rRNA gene sequence, five taxa previously undescribed in veterinary medicine were identified; *S. caprae*, *S. succinus*, *Propionibacterium acnes*, *P. faecalis* and *Bacillus subtilis* (Płoneczka-Janeczko et al., 2017). Unlike in Ukraine, this issue is receiving considerable attention in foreign countries. Based on

the dangers for humans of *S. aureus* isolated from conjunctivitis in cats, and given its lack of sensitivity to many antibacterial agents, the World Association of Veterinary Dermatologists (WAVD) offers recommendations for diagnosis, therapy, and hygiene and disinfection for staphylococcal infection (Morris et al., 2017). Thus, most authors are limited to isolating isolates without determining its effect on the body, in particular immune status. It should be noted that studies on the prevalence of conjunctivitis caused by *S. aureus* in cats and their role in human morbidity due to transmission from pets have not been conducted. In addition, the pathogenetic aspects remain insufficiently studied, which determines the relevance of the study of this pathology. Based on the above, the aim of the study was to study the prevalence of conjunctivitis in cats and the role of *S. aureus* in the pathogenesis of this zoonotic disease.

## Material and methods

The research was carried out at the Department of Surgery and Obstetrics of Agricultural Animals of Dnipro State Agrarian and Economic University, two state (Samara, Shevchenkivsky and Soborny districts) and two private (FOP Alimov and PE "Vetol") veterinary medicine clinics in Dnipro between 2015 and 2018, in accordance with the requirements of the "European Convention on the Protection of Vertebrate Animals" (Strasbourg, 1986) and the Law of Ukraine on the Protection of Animals Against Cruelty (2006). The protocol of the research programme was approved by the conclusion of the Commission on Bioethics of the Dnipro State Agrarian and Economic University. Monitoring studies were performed by analyzing the records of the registration of sick animals in the outpatient journals of these institutions. Clinical studies were made in the Department of Surgery and Obstetrics for Animals; laboratory studies were performed at the Research Center for Safety and Environmental Control of Resources of the Agrarian-Industrial Complex of the Dnipro State Agrarian and Economic University and the Dnipro Regional Veterinary Laboratory on 16 clinically healthy animals of 1 day, 3 months and 3 years old; 5 clinically healthy and 10 outbred cats with purulent keratoconjunctivitis aged 12–14 months, weighing 3.5–4.0 kg.

Animals were kept in individual cages measuring 0.9 m<sup>2</sup> throughout the study period. Before the experiment, the animals were dewormed (cat Drontal), their clinical status, hematological and biochemical serum levels were determined, washings were taken from the conjunctival bladder for seeding on nutrient media (meat-peptone broth, sucrose broth-peptone agar, sucrose agar, staphylococcal agar No 110, Saburo agar with chloramphenicol and cycloheximide). Species belonging to staphylococci were determined by lecithinase plasma-coagulating, hemolytic activity and decay of mannitol under anaerobic conditions. Antibiotic sensitivity was determined using paper discs. In the blood of the animals we determined indicators of morphological status: leukocytes – melangery method in the Goryaev counting chamber; the leukocyte formula was deduced by counting 200 leukocytes in smears stained with the Romanovsky–Gimza. The phagocytic activity of neutrophils (PAN) of peripheral blood was studied by a test method (from *S. epidermidis* strain 9198), followed by counting the phagocytic number in stained smears, index of completed phagocytosis. The nitrosine tetrazolium spontaneous test was evaluated by the reduction of nitrosine tetrazolium. The percentage of T-lymphocytes, their subpopulations and B-lymphocytes was determined by the reaction of rosette formation with erythrocytes, which adsorbed monoclonal antibodies against receptors CD3 (T-lymphocytes), CD4 (T-helper), CD8 (T-suppressors), CD16 (natural killers), CD19 (B-lymphocytes) (Lora et al., 2000). The liver biosynthetic function was evaluated by the level of total protein (refractometrically) and protein fractions (nephelometric method). The content of class A, E, G, and M immunoglobulins was determined by the enzyme immunoassay and the circulating immune complexes by the polyethylene glycol precipitation method (Grinevich et al., 1981). The activity of total complement was evaluated by its hemolytic activity (50% hemolysis) in a unified method with ram erythrocytes in the presence of rabbit serum. The activity of the complement component C<sub>3</sub> was determined by the enzyme-linked immunosorbent assay, and the complement component C<sub>4</sub> by the immunoturbidimetric method on a Cobas 6000 analyzer.

The presence and distribution of polypeptides that reacted with specific *S. aureus* antigens were determined in conjunctiva and corneal homogenates, chamber fluid, and cat blood by electrophoresis and immunoblotting. Electrophoresis of protein antigens was performed in polyacrylamide gel by the method of Laemmli et al. (1970). Electrophoretic transfer of antigens from the gel to the nitrocellulose membrane was carried out by the method of Towbin et al. (1979). As a positive control, we used reference rabbit serum to *S. aureus* (strain 209).

The work used the program "LabWork 4.0" (UVP, 2001) to scan and compare the intensity of polypeptide zones on the nitrocellulose membrane after immunoblotting. The colour intensity of the zones of *S. aureus* polypeptides in the control group was taken as 1 (100%). Conditional units in which the *S. aureus* content was expressed were calculated by assigning the relative zone density (%) to the protein content in the sample (µg).

Cats with purulent keratoconjunctivitis were subjected to the same investigation procedures on the first, third and seventh days of the disease, but prior to the experiment, they were sampled (serum and scrapers) for analysis for herpes (FHV-1), adenovirus, chlamydia, mycoplasmosis and toxoplasmosis by real-time polymerase chain reaction and enzyme immunoassay.

Statistical processing of the results was performed using Statistica 10 (StatSoft Inc., USA, 2011). A Bonferroni-corrected ANOVA was used to determine the difference between the samples.

## Results

In the veterinary clinics involved in the research, an average of 1,045 animals are registered annually, among which 41.5% are cats suffering from surgical pathology, and the incidence is higher among males. In each of the veterinary hospitals, 7.7% of sick cats have eye diseases. Metis (73.2%) make up the vast majority of patients. At the same time, ophthalmic pathology is most commonly reported in cats of Persian, British breeds and sphinxes.

In the structure of ophthalmic pathology, conjunctivitis accounts for 6.7% of the number of patients with surgical diseases and 35.5% – of the total number of eye diseases (Fig. 1). In 81.0% of cases, conjunctivitis is diagnosed with bilateral lesions, and 39.2% of animals have purulent-catarhal disease. In most cases, the cause of the lesion is coccal flora colonization (staphylococci), the remaining cases are allergic. Unilateral conjunctivitis usually occurs as a result of trauma, but in some animals the etiology of the disease is not clear.

Keratoconjunctivitis is one of the most commonly reported eye pathologies. 5.5% of surgically ill animals are diagnosed with this disease, but keratoconjunctivitis accounts for 29.2% among eye diseases.

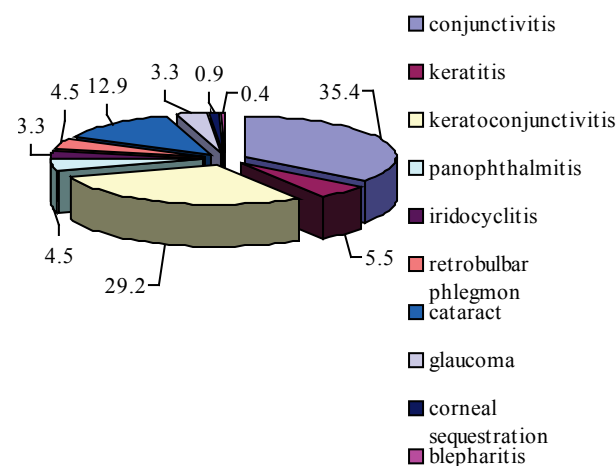


Fig. 1. Nosological profile of ophthalmopathology in cats in Dnipro (2015–2018, %, n = 1323)

Keratoconjunctivitis occurs in the form of purulent catarhal or serious catarhal inflammation and in the absolute majority of cases (84.4%) is bilateral. The primary etiological factor of the disease is the primary colonization of the coccal flora or its development on the back-

ground of an allergic condition, in particular with paranasal adenitis, although, in 15.6% of the animals the disease is traumatic in origin. It is also interesting that 6.7% of cases of keratoconjunctivitis have a chlamydial etiology – four cases of chlamydia of the eyes are registered in two private hospitals, according to which the proportion of chlamydial keratoconjunctivitis is 21%. Chlamydia is not recorded in other veterinary hospitals, possibly because of the lack of conditions for diagnosis.

Cat diseases of the eyes are mostly recorded in the cold season. By seasonality, the incidence is as follows: winter – 41.6%; spring – 23%; summer – 9.5%; autumn – 25.9%. More detailed analysis revealed that males are more likely to fall ill in winter and females are more likely to fall ill in the autumn. Ophthalmic pathology is diagnosed in patients aged one month to eighteen years, in particular: up to 3 months – 15.8%, 3–6 months – 9.0%, up to one year – 11.6%, three to five years – 16%, ten years – 11.9%, more than 10 years – 17.4%.

The conjunctival cavity of healthy cats is a harbour of a variety of microorganisms, including *S. albus*, *S. aureus*, *Bacillus* sp., that enter the conjunctival bladder from the external environment, however, humoral and cellular defense factors are able to control their pathogenic effects. It should be noted that superficial mechanical scarification of the connective eye tissue does not cause clear clinical signs of inflammation (tear, light phobia and blepharospasm were absent). Only scarification sites have superficially moderately hyperemic erosions that gradually decrease and completely epithelialize for 8–9 days, even without treatment.

The seeding of material from the conjunctiva of clinically healthy cats in nutrient media in all cases showed an increase in microflora, including: 1 case of *Bacillus* sp. (O-form), which appeared to be insensitive to antibiotics; 1 case of *Bacillus* sp. (R-form), which was sensitive to antibiotics with a growth inhibition zone, respectively: gentamicin – 20 mm, levomycetin – 15 mm, tetracycline, norfloxacin and enoxil – 12 mm; 4 cases of *S. albus*, which showed sensitivity to antibiotics with growth inhibition zone, respectively: ampiclox – 30 mm, ceftriaxone – 30 mm, clomoxyl – 29 mm, lincomycin – 24 mm, levomycetin – 23 mm, floran – 22 mm; 6 cases of *S. epidermidis* susceptible to antibiotics with growth inhibition zone, respectively: ampiclox and clomoxyl – 30 mm, ceftriaxone – 28 mm, floran – 24 mm, gentamycin – 20 mm, lincomycin – 17 mm; 4 cases of *S. aureus*, which are sensitive to antibiotics with growth inhibition zone, respectively: ampiclox – 31 mm, ceftriaxone – 30 mm, clomoxyl – 30 mm, lincomycin – 28 mm, levomycetin – 25 mm, floran – 22 mm. Among the detected microorganisms, the vast majority were staphylococci, including *S. albus* and *S. aureus* accounted for 25%, and *S. epidermidis* – 37.5%.

In the conjunctival smears of clinically healthy cats, a positive response to *C. psittaci* was detected in 3 animals by real-time polymerase chain reaction. In addition, one of the chlamydia-responsive animals showed an even more positive response to *M. felis*.

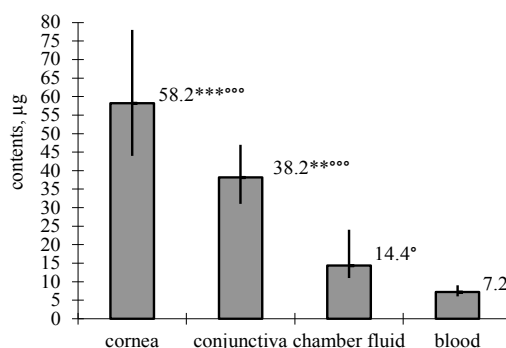
The purulent inflammation of the conjunctiva and cornea is manifested by rather pronounced local symptoms with varying degrees of visual impairment. However, according to current concepts of inflammation, this pathological process should be considered conditionally local. From this point of view, the data we have obtained regarding the distribution of pathogens in the body and their effect on the function of other organs and systems are of particular interest. Samples of the conjunctiva, cornea, intraocular fluid and blood of cats suffering from artificially induced purulent (staphylococcal) keratoconjunctivitis revealed polypeptides that respond to specific *S. aureus* antigens.

The test specimens exhibit characteristic differences in the content of *S. aureus* antigens, which is evidence of the differential distribution of the infectious agent, probably due to the complex of circumstances and conditions, including the characteristics of the investigated substrates and tropism of the pathogen (Fig. 2). The highest concentrations of *S. aureus* antigen were detected in the cornea (58.2 µg) and conjunctiva (38.2 µg). Intraocular fluid and blood receive respectively 14.4 and 7.2 µg of the infectious agent.

The dynamics of immunological parameters (Table 1) show a significant (except IgG) increase in the content of immunoglobulins and CIC: IgA – by 102.0%, IgE – by 40.3%, IgM – by 54.2%; circulating immune complexes – by 64.2%, as well as a clear activation of the complement system. On the seventh day, similar changes in the level of

circulating immune complexes (by 74.5%) and immunoglobulins were observed, but the increase in IgG level (by 36.2%) became significant ( $P < 0.05$ ). In cats, there is an unreliable increase in the activity of total complement, with the maximum indicator (115.5%) reached on the third day of observation. The dynamics of the C<sub>3</sub>-component are fluctuating and unreliable, namely: on the first day of research the level of C<sub>3</sub> increased by 2.5%, on the third day it was 8.9% less than the initial one, and on the seventh day it again exceeded it by 3.8%. The indicators of C<sub>4</sub> almost repeat the overall dynamics of C<sub>3</sub>, but on the third day there was a significant decrease ( $P < 0.05$ ).

The number of phagocytic neutrophils gradually increased by 10.2–18.4% (Table 2), reaching its maximum value by the seventh day of development of purulent keratoconjunctivitis (133.6%). The phagocytic index in the first three days of observation tended to decrease (by 7.0–16.3%), and by the seventh day it already significantly exceeded the original value by 76.7%. Despite the ambiguous dynamics of the phagocytic index, an increase in the index of complete phagocytosis (up to 50.0% on the seventh day) was observed in the course of the development of the inflammatory process in the blood of sick cats.



**Fig. 2.** Distribution of *S. aureus* in blots of the cornea, conjunctiva, internal fluid, and blood of Dnipro cats suffering from purulent keratoconjunctivitis (2015–2018, n = 10); ° –  $P < 0.05$ ; \*\* –  $P < 0.01$ ; \*\*\*\* –  $P < 0.001$ , about content: \* – in the chamber fluid, ° – blood by comparison with the Bonferroni-corrected ANOVA

**Table 1**

Dynamics of indicators of humoral immunity of cats suffering from purulent keratoconjunctivitis ( $\bar{x} \pm SD$ )

Indicators	Animals			
	clinically healthy, n = 5	patients with purulent keratoconjunctivitis, n = 10		
		1 day	3 day	7 day
Total protein, g/L	60.2 ± 1.10	62.0 ± 1.20	63.0 ± 1.10	65.0 ± 1.10
Albums, g/L	29.0 ± 0.97	29.0 ± 0.98	27.7 ± 1.00	29.0 ± 1.20
Globulins, g/L	30.2 ± 0.89	32.0 ± 0.87	36.0 ± 1.40	36.0 ± 1.50
IgA, g/L	2.0 ± 0.19	2.3 ± 0.07	4.0 ± 0.52*	3.8 ± 0.33
IgE, IU/mL	2.9 ± 0.04	3.4 ± 0.11	4.1 ± 0.06	4.0 ± 0.10*
IgG, g/L	6.9 ± 0.19	7.1 ± 0.15	7.4 ± 0.14	9.4 ± 0.37*
IgM, g/L	2.1 ± 0.28	2.5 ± 0.13	3.3 ± 0.11*	3.6 ± 0.11*
Circulating immune complexes, conventional units	28.0 ± 2.70	30.0 ± 1.79	46.0 ± 1.60*	49.0 ± 1.40*
Total complement activity, conventional units	57.0 ± 2.80	62.0 ± 2.40	66.0 ± 1.20	63.0 ± 1.30
C3 component of complement, g/L	0.80 ± 0.02	0.80 ± 0.02	0.70 ± 0.02	0.80 ± 0.02
C4 component of complement, g/L	0.30 ± 0.02	0.30 ± 0.01	0.28 ± 0.01*	0.30 ± 0.01

Note: \* –  $P < 0.05$  relatively clinically healthy animals.

## Discussion

Conjunctivitis, along with keratoconjunctivitis and corneal ulcers, is widespread not only in humans but also in animals (Spadea et al., 2018), as confirmed by our observations in Dnipro. Ophthalmic diseases are

accompanied by similar clinical features (Giudici & Pressanti, 2014), so determining the etiological factors that may be represented by zoonotic pathogens plays an important role in the complex diagnosis and development of treatment interventions (Gerding et al., 1990).

**Table 2**  
Dynamics of indicators of cellular immunity  
of cats suffering from purulent keratoconjunctivitis ( $\bar{x} \pm SD$ )

Indicators	Animals			
	clinically healthy, n=5	patients with purulent keratoconjunctivitis, n=10		
		1 day	3 day	7 day
Leukocytes, G/L	7.9 ± 0.42	8.0 ± 0.27	8.5 ± 0.19*	8.4 ± 0.11
Eosinophils, %	3.4 ± 1.08	3.5 ± 0.67	3.7 ± 0.22	3.8 ± 0.26
Rod-core, %	3.2 ± 0.73	3.8 ± 0.26	3.6 ± 0.23	4.0 ± 0.22
Segmented nuclear, %	54.0 ± 1.80	53.0 ± 1.60	56.0 ± 1.30	54.0 ± 0.94
Lymphocytes, %	39.0 ± 2.30	39.0 ± 1.60	35.0 ± 1.08	36.0 ± 0.90
Monocytes, %	0.7 ± 0.32	1.1 ± 0.25	2.3 ± 0.16*	2.2 ± 0.14*
CD3, %	52.0 ± 2.80	48.0 ± 1.70	45.0 ± 1.20*	38.0 ± 1.90*
CD4, %	34.0 ± 1.90	29.0 ± 0.89	30.0 ± 0.89	29.0 ± 1.20
CD8, %	21.0 ± 2.3	25.0 ± 0.83	28.0 ± 1.03	30.0 ± 0.66
CD16, %	22.0 ± 2.20	29.0 ± 1.04	31.0 ± 0.94*	32.0 ± 1.50*
CD19, %	22.0 ± 0.86	23.3 ± 0.90	22.0 ± 1.09	20.5 ± 1.30
Spontaneous NBT, %	4.5 ± 0.15	4.6 ± 0.32	5.9 ± 0.44*	4.9 ± 0.16*
Phagocytic activity of neutrophils, %	34.0 ± 3.30	38.0 ± 1.30	40.5 ± 1.50*	46.0 ± 1.20*
Phagocytic number	4.3 ± 0.32	4.0 ± 0.31	3.6 ± 0.17	7.6 ± 0.32*
Index of complete phagocytosis	1.8 ± 0.21	2.2 ± 0.14	2.5 ± 0.18*	2.7 ± 0.16*

Note: see Table 1.

Statistical analysis showed a significant prevalence of conjunctivitis in domestic cats, which is consistent with reports from other researchers (Płoneczka-Janeczko et al., 2017), who also believe that in addition to infectious factors, this disease can be caused by trauma, hypersensitivity reactions, etc. The conjunctival sac has been found to be inhabited by more diverse associations of microflora than previously thought, the most common of which are cat herpes virus (FHV-1), *C. felis* and *M. felis*, causing serous mucous-purulent discharge from the eye. Hillström et al. (2012) argue that cytological examination of conjunctivitis of cats allows one to determine the type of inflammation and to detect some microorganisms, in particular *C. felis*, but their results are contradictory.

The occurrence of hospital infections in veterinary clinics, in particular staphylococcal (Quitoco et al., 2013) and the widespread use of antibacterial therapy are among the main causes of the high likelihood of human infection, especially from the point of view of multiple pharmacological resistance of microorganisms (Palchykov et al., 2019; Zaharskyi et al., 2019). It is therefore advisable to conduct training programmes for monitoring not only productive but also small animals (Wieler et al., 2011). Because MRSA lines isolated from infected pets often reflect epidemic human strains circulating in the same region a successful disease control strategy requires coordinated efforts by human and veterinary medicine, in line with the "Single Health" concept (Vincze et al., 2014).

In this case, Worthing et al. (2018) indicate that the transmission of *S. aureus* and *S. pseudintermedius* by veterinary staff to animals and vice versa is restricted in non-outbreak conditions.

Human medicine has proven that *S. aureus* is a major causative agent of eye diseases, capable of infecting the lacrimal duct, eyelids, conjunctiva, cornea, anterior, posterior, and vitreous chambers of the eye. In addition to causing skin and soft tissue infections, osteomyelitis, endocarditis, sepsis and pneumonia, *S. aureus* is one of the most common causes of eye infections, including blepharitis, dacryocystitis, conjunctivitis, keratitis and endophthalmitis (O'Callaghan, 2018). *S. aureus* is thought to accelerate the development of experimental allergic conjunctivitis (Chung et al., 2009) and to activate conjunctival inflammation (McGilligan et al., 2013). The virulence of different strains of *S. aureus* for the conjunctiva varies (McCormick et al., 2011). But as far as cats are concerned, these issues are still poorly understood today.

Infection of the external structures of the eye is one of the most common types of diseases (Armstrong, 2007). Bacterial conjunctivitis is increasingly becoming an independent disease that can be caused by "normal" microflora, in particular *S. aureus*, or by its pathogenic strains (Diamant & Hwang, 1999), which is consistent with the results of our studies. The studies conducted add to and confirm the message (Weese et al., 2015) that associations of microorganisms that populate the conjunctiva play an important role in the protection against pathogenic infections and at the same time are a source of potential pathogens. The microbial flora of the conjunctiva interacts closely with the immune system, and changes in an animal's immune status can lead to some changes in this association of microorganisms. Pathogens are staphylococci, which are widespread on mucosal surfaces and can be associated with a wide range of infections, including conjunctivitis. Therefore, we can assume that this microflora is not normal for the conjunctiva. As our research has shown, primary bacterial eye infections associated with corneal and conjunctival lesions are quite common.

The high incidence of staphylococci and their role in the pathogenesis of eye diseases in cats confirms the results presented by other researchers (Adler et al., 2007; Lin & Petersen-Jones, 2008), which is explained by the presence in the conjunctival sac of healthy animals of *S. aureus*, *S. saprophyticus*, *Bacillus* sp., *E. coli* and *Enterobacter* sp. (Cardoso et al., 2012). The sensitivity to antibacterial agents is consistent with the data of Goldreich et al. (2019). In particular, staphylococci are the most common gram-positive bacteria secreted during keratitis. Second-generation fluoroquinolones, ciprofloxacin, aminoglycosides, and gentamicin have been found to be highly effective against most isolates (Lin & Petersen-Jones, 2008). According to our research, conjunctival staphylococci are sensitive to most antibiotics. In addition, staphylococci also account for the largest number of microorganisms detected.

Conjunctivitis in cats has a different etiology, which is confirmed by the analysis of reports from other researchers. In particular, in cats with chronic conjunctivitis DNA of *C. felis* and FHV-1 was found in 6.7% and 33.3% of patients, respectively, despite the absence of joint infections with both pathogens (Wieliczko & Płoneczka-Janeczko, 2010). *Chlamydia* and *Mycoplasma* are an important cause of acute and chronic conjunctivitis in cats (Sykes, 2005; Low et al., 2007).

The assumptions about the polyetiological nature of conjunctivitis in cats are supported by studies by other authors. In particular, cat conjunctivitis is often associated with herpes viruses, mycoplasmas, and chlamydia (Sjödahl-Essén et al., 2008). The authors point out that the presence of these pathogens may not be associated with the primary disease, but is a consequence of the weakening of the body's defenses through the primary disease, or may be the cause of the primary disease. The authors were unable to establish a correlation between the positive results of the diagnostic tests and the degree of clinical manifestation. It should be noted that by polymerase chain reaction smears of the conjunctiva of clinically healthy cats, we also isolated *C. psittaci* and *M. felis*. But it is important to note that initial diagnosis should not be based solely on laboratory testing. Researchers indicate that the presence of *C. felis* is associated with conjunctivitis, whereas the detection of the herpes virus does not correlate significantly with the clinical signs of the disease. This suggests that the polymerase chain reaction alone does not provide an accurate diagnosis of conjunctivitis associated with the herpes virus (Rampazzo et al., 2008). A large percentage of chlamydial conjunctivitis in cats was determined by our studies.

According to Aftab et al. (2019), conjunctivitis is not characterized by seasonality against the background of predominance of gram-positive bacteria – *S. epidermidis* (43.2%),  $\beta$ -hemolytic streptococcus (18.9%), *S. aureus* (17.9%) and *E. coli* (11.5%). At the same time, we found that their registration in the cold season was significantly higher, although gram-positive microorganisms were most often also isolated. This may be due to the fact that, in addition to bacterial microflora associations, the level of morbidity is also influenced by other factors: anatomical disorders, traumas and hypersensitivity reactions, either alone or together with infectious factors.

With only information on the colonization of the conjunctival sac of *S. aureus*, we have established the peculiarities of its distribution in tissues and fluids of the eye: the highest concentration is established in



the cornea and conjunctiva against the background of much lower concentration in the chamber fluid and blood, which can be explained by the activation of protective mechanisms, given the ability of *S. aureus* to cause intraocular inflammation and loss of retinal function (Kumar & Kumar, 2015). The activation of the conjunctivitis complement system in cats, which is caused by *S. aureus*, has been proven to be consistent with the message of other researchers, including Gilger (2008). Activation of the complement system is controlled by regulatory proteins that determine its intensity, sufficient to destroy the pathogenic factor (Sohn et al., 2000). Frequent prolonged exposure to systemic or local inflammatory stimuli may result in low levels of complement activation and process generalization (Crowley et al., 2018). The results of the dynamic profile of complement activation are valuable for a better understanding of the mechanism of conjunctivitis in cats and the development of pathogenetically sound treatment guidelines.

Despite the important role of neutrophils in the mechanisms of innate immunity, we have not established significant changes in their blood content for conjunctivitis caused by *S. aureus*, which is probably related to the ability of *S. aureus* to produce protection factors by escaping recognition (McGuinness et al., 2016; Rasigade, 2018).

In most cases, the inflammatory response is accompanied by a decrease in the level of acute-phase proteins by Cerón et al. (2008), however, we did not detect significant changes in albumin content due to purulent conjunctivitis caused by *S. aureus*.

The established enhancement of both cellular and humoral defense mechanisms is explained by the activation of factors of the innate immune response (Yoong & Pier, 2010).

Analyzing the results obtained, it can be stated that eye microflora in normal and during pathological conditions is an important aspect of the evaluation of eye diseases. During the examination of the microbial flora, it was found that gram-positive bacteria are predominant in the conjunctival cavity both in norms and pathologies. Injuries to the eyes can lead to reproduction and potential pathogenicity of the normal microflora of the eye, which is consistent with our findings. The diversity of bacterial, fungal, viral and other microbial isolates influences the diagnosis and treatment of eye diseases (Paul & Gerding, 1990).

The results obtained may be useful in the diagnosis and treatment of conjunctivitis, as certain types of staphylococci may have different mechanisms of pathogenicity, pathogenesis, or transmission features. The authors suggest that *S. aureus* is a natural bacterial flora in cats, especially in animals that are kept in close contact with their owners (Nagase et al., 2002). In the group of healthy cats kept in households, a greater variety of staphylococcus species was observed than in wild cats. Researchers point to the fact that conditionally pathogenic microflora can cause a wide range of complications and report that the morbidity, antibiotic resistance of different types of staphylococci in cats depends on the state of the body's defenses. A statistically significant correlation was observed between cat health and staph infection (Bierowiec et al., 2019). The high frequency of colonization of cats by staphylococci is confirmed by Ma et al. (2019), who isolated them in 73.8% of animals, which is consistent with the results of our studies. Antibiotic sensitivity in different types of staphylococci varies. In animals, the pathogenic potential of these microorganisms is not yet fully understood (Gandolfi-Decristophoris et al., 2013).

Of particular concern to scientists in the field of public and animal health is the methicillin-resistant *S. aureus*. In this regard, the importance of providing effective and reliable methods for its identification is emphasized (Medhus et al., 2013; Morris et al., 2006), which in the long run confirms the need for research to investigate the role of staphylococci in the incidence of conjunctivitis and keratitis in cats.

The findings are consistent with the concept of the Working Group of the International Society for Infectious Diseases of Companion Animals, which substantiates the feasibility of further studies of bacterial diseases of cats to develop more effective recommendations for their treatment and prevention (Lappin et al., 2017).

## Conclusions

Cat diseases are very common, with a large proportion of conjunctivitis (35.4%) and keratoconjunctivitis (29.2%), most of which were reported in the cold season, and were caused by mechanical trauma, coccal and chlamydial infections. Among the detected microorganisms, the vast majority (81.9%) were staphylococci, including *S. albus*, *S. aureus*, *S. epidermidis*. In spite of the high degree of sensitivity of the detected microflora to the most common antibiotics in veterinary practice, we consider it logical to assume that this microflora is normal and conditionally pathogenic for the conjunctiva. Features of antigen distribution in blood, tissues, and eyeball fluid in staphylococcal keratoconjunctivitis may be evidence of the ability of staphylococci to ignore cellular protective barriers, although the highest antigen concentration is found in the cornea and conjunctiva. Dynamics of significant increase in the content of circulating immune complexes, immunoglobulins, powerful activation of phagocytosis and the complement system in the classical way are evidence of distinct cellular and humoral reactions to the infectious agent.

## References

- Adler, K., Radeloff, I., Stephan, B., Greife, H., & Hellmann, K. (2007). Bacteriological and virological status in upper respiratory tract infections of cats (cat common cold complex). *Berliner und Münchener tierärztliche Wochenschrift*, 120(3–4), 120–125.
- Aftab, G., Rajaei, S. M., Pot, S. A., & Faghihi, H. (2019). Seasonal effects on the corneconjunctival microflora in a population of Persian cats in Iran. *Topics in Companion Animal Medicine*, 34, 30–32.
- Armstrong, R. A. (2007). The microbiology of the eye. *Ophthalmic and Physiological Optics*, 20(6), 429–441.
- Bierowiec, K. A., Korzeniowska-Kowal, A., Wzorek, A., Rypula, K., & Gamian, A. (2019). Prevalence of *Staphylococcus* species colonization in healthy and sick cats. *BioMed Research International*, 2019, 4360525.
- Bierowiec, K., Ploneczka-Janeczko, K., & Rypula, K. (2014). Cats and dogs as a reservoir for *Staphylococcus aureus*. *Postępy Higieny i Medycyny Doświadczalnej*, 18(68), 992–997.
- Bierowiec, K., Ploneczka-Janeczko, K., & Rypula, K. (2016). Prevalence and risk factors of colonization with *Staphylococcus aureus* in healthy pet cats kept in the city households. *BioMed Research International*, 2016, 3070524.
- Bramble, M., Morris, D., Tolomeo, P., & Lautenbach, E. (2011). Potential role of pet animals in household transmission of methicillin-resistant *Staphylococcus aureus*: A narrative review. *Vector-Borne and Zoonotic Diseases*, 11(6), 617–620.
- Büttner, J. N., Schneider, M., Csokai, J., Müller, E., & Eule, J. C. (2019). Microbiota of the conjunctival sac of 120 healthy cats. *Veterinary Ophthalmology*, 22(3), 328–336.
- Cardoso, M. G., Pinho, L. A., Monteiro, R. do S. D., Novaes, J. A., Espinheiro, R. de F., & Dias, H. L. T. (2012). Microbiota bacteriana aeróbica conjuntival de cães e gatos sadios da cidade de Belém, Pará. *Archives of Veterinary Science*, 17, 239–241.
- Cerón, J. J., Eckersall, P. D., & Martínez-Subiela, S. (2005). Acute phase proteins in dogs and cats: Current knowledge and future perspectives. *Veterinary Clinical Pathology*, 34(2), 85–99.
- Chung, S. H., Nam, K. H., & Kweon, M. N. (2009). *Staphylococcus aureus* accelerates an experimental allergic conjunctivitis by toll-like receptor 2-dependent manner. *Clinical Immunology*, 131, 170–177.
- Crowley, M. A., Delgado, O., Will-Orrego, A., Buchanan, N. M., Anderson, K., Jaffee, B. D., Dryja, T. P., & Liao, S.-M. (2018). Induction of ocular complement activation by inflammatory stimuli and intraocular inhibition of complement factor D in animal models. *Investigative Ophthalmology and Visual Science*, 59, 940–951.
- Diamant, J. I., & Hwang, D. G. (1999). Therapy for bacterial conjunctivitis. *Ophthalmology Clinics of North America*, 12(1), 15–20.
- Drougka, E., Foka, A., Koutinas, C. K., Jelastopulu, E., Giormezis, N., Farmaki, O., Sarrou, S., Anastassiou, E. D., Petinaki, E., & Spiliopoulou, I. (2016). Interspecies spread of *Staphylococcus aureus* clones among companion animals and human close contacts in a veterinary teaching hospital. A cross-sectional study in Greece. *Preventive Veterinary Medicine*, 126, 190–198.
- Espinolaz, M. B., & Lilenbaum, W. (1996). Prevalence of bacteria in the conjunctival sac and on the eyelid margin of clinically normal cats. *Journal of Small Animal Practice*, 37(8), 364–366.
- Gandolfi-Decristophoris, P., Regula, G., Petrini, O., Zinsstag, J., & Schelling, E. (2013). Prevalence and risk factors for carriage of multi-drug resistant *Staphylococcus aureus* in healthy cats and dogs. *Journal of Veterinary Science*, 14(4), 449–456.
- Gerding, P. A., & Kakoma, I. (1990). Microbiology of the canine and feline eye. *Veterinary Clinics of North America*, 20(3), 615–625.
- Gilger, B. C. (2008). Immunology of the ocular surface. *Veterinary Clinics of North America*, 38(2), 223–231.

- Giudici, V., & Pressanti, C. (2014). Le congiuntiviti e le blefariti acute. *Summa, Animali da Compagnia*, 31(4), 24–31.
- Goldreich, J. E., Franklin-Guild, R. J., & Ledbetter, E. C. (2019). Feline bacterial keratitis: Clinical features, bacterial isolates, and *in vitro* antimicrobial susceptibility patterns. *Veterinary Ophthalmology*, 22(5), 563–565.
- Grinevich, J. A. (1981). Opredelenie immunnih kompleksov v krovi onkologicheskikh bol'nyh [Determination of immune complexes in the blood of cancer patients]. *Laboratomoe Delo*, 8, 493–496 (in Russian).
- Hartmann, A. D., Hawley, J., & Werckenthin, C. (2010). Detection of bacterial and viral organisms from the conjunctiva of cats with conjunctivitis and upper respiratory tract disease. *Journal of Feline Medicine and Surgery*, 12, 10, 775–782.
- Hillström, A., Tvedten, H., Källberg, M., Hanas, S., Lindhe, A., & Ström Holst, B. (2012). Evaluation of cytologic findings in feline conjunctivitis. *Veterinary Clinical Pathology*, 41(2), 283–290.
- Kielbowicz, Z., Płoneczka-Janeczko, K., Bania, J., Bierowiec, K., & Kielbowicz, M. (2015). Characteristics of the bacterial flora in the conjunctival sac of cats from Poland. *Journal of Small Animal Practice*, 56(3), 203–206.
- Kishkun, A. A. (2006). Immunologicheskii i serologicheskii issledovaniya v klinicheskoi praktike. [Immunological and serological research in clinical practice] *Medicinskoe Informacionnoe Agenstvo, Moscow* (in Russian).
- Köck, R., Ballhausen, B., Bischoff, M., Cuny, C., Eckmanns, T., Fetsch, A., Harmsen, D., Goerge, T., Oberheitmann, B., Schwarz, S., Selhorst, T., Tenhagen, B. A., Walther, B., Witter, W., Ziebuhr, W., & Becker, K. (2014). The impact of zoonotic MRSA colonization and infection in Germany. *Berliner und Münchener tierärztliche Wochenschrift*, 127(9–10), 384–398.
- Kottler, S., Middleton, J. R., Perry, J., Weese, J. S., & Cohn, L. A. (2010). Prevalence of *Staphylococcus aureus* and methicillin-resistant *Staphylococcus aureus* carriage in three populations. *Journal of Veterinary Internal Medicine*, 24(1), 132–139.
- Kumar, A., & Kumar, A. (2015). Role of *Staphylococcus aureus* virulence factors in inducing inflammation and vascular permeability in a mouse model of bacterial endophthalmitis. *PLoS One*, 10(6), e0128423.
- Lane, M. J., Roy, A. F., Kearney, M. T., & Pucheu-Haston, C. M. (2018). Characterization, distribution, antimicrobial resistance and resistance risk factors in staphylococci isolated from cats from 2001 to 2014. *Veterinary Medicine and Science*, 4(4), 315–325.
- Lappin, M. R., Blondeau, J., Boothe, D., Breitschwerdt, E. B., Guardabassi, L., Lloyd, D. H., Papich, M. G., Rankin, S. C., Sykes, J. E., Tumidge, J., & Weese, J. S. (2017). Antimicrobial use guidelines for treatment of respiratory tract disease in dogs and cats: Antimicrobial guidelines Working Group of the International Society for Companion Animal Infectious Diseases. *Journal of Veterinary Internal Medicine*, 31(2), 279–294.
- Lin, C.-T., & Petersen-Jones, S. M. (2008). Antibiotic susceptibility of bacteria isolated from cats with ulcerative keratitis in Taiwan. *Journal of Small Animal Practice*, 49(2), 80–83.
- Lora, G., Fisher, T., & Adel'man, D. (2000). Klinicheskaja immunologija i allelogologija [Clinical immunology and allergology]. *Praktika, Moscow* (in Russian).
- Low, H. C., Powell, C. C., Veir, J. K., Hawley, J. R., & Lappin, M. R. (2007). Prevalence of feline herpesvirus 1, *Chlamydomphila felis*, and *Mycoplasma* spp. DNA in conjunctival cells collected from cats with and without conjunctivitis. *American Journal of Veterinary Research*, 68(6), 643–648.
- Ma, G. C., Worthing, K. A., Ward, M. P., & Norris, J. M. (2019). Commensal *Staphylococcus aureus* including methicillin-resistant *Staphylococcus aureus* from dogs and cats in remote New South Wales, Australia. *Microbial Ecology*, 2019, in press.
- Marquart, M. E. (2011). Animal models of bacterial keratitis. *Journal of Biomedicine and Biotechnology*, 2011, 680642.
- McCormick, C. C., Caballero, A. R., Balzi, C. L., Tang, A., Weeks, A., & O'Callaghan, R. J. (2011). Diverse virulence of *Staphylococcus aureus* strains for the conjunctiva. *Journal Current Eye Research*, 36, 14–20.
- McGilligan, V. E., Gregory-Ksander, M. S., Li, D., Moore, J. E., Hodges, R. R., Gilmore, M. S., Moore, T. C. B., & Dartt, D. A. (2013). *Staphylococcus aureus* activates the NLRP3 inflammasome in human and rat conjunctival goblet cells. *PLoS One*, 8, e74010.
- McGuinness, W. A., Kobayashi, S. D., & DeLeo, F. R. (2016). Evasion of neutrophil killing by *Staphylococcus aureus*. *Pathogens*, 5(1), e32.
- Medhus, A., Sletteaes, J. S., Marstein, L., Larssen, K. W., & Sunde, M. (2013). Methicillin-resistant *Staphylococcus aureus* with the novel mec C gene variant isolated from a cat suffering from chronic conjunctivitis. *Journal of Antimicrobial Chemotherapy*, 68(4), 968–969.
- Morris, D. O., Loeffler, A., Davis, M. F., Guardabassi, L., & Weese, J. S. (2017). Recommendations for approaches to methicillin-resistant staphylococcal infections of small animals: Diagnosis, therapeutic considerations and preventative measures: Clinical Consensus Guidelines of the World Association for Veterinary Dermatology. *Veterinary Dermatology*, 28(3), 304–369.
- Morris, D. O., Mauldin, E. A., O'Shea, K., Shofer, F. S., & Rankin, S. C. (2006). Clinical, microbiological, and molecular characterization of methicillin-resistant *Staphylococcus aureus* infections of cats. *American Journal of Veterinary Research*, 67(8), 1421–1425.
- Nagase, N., Sasaki, A., & Yamashita, K. (2002). Isolation and species distribution of *Staphylococci* from animal and human skin. *Journal of Veterinary Medical Science*, 64(3), 245–250.
- O'Callaghan, R. J. (2018). The pathogenesis of *Staphylococcus aureus* eye infections. *Pathogens*, 7(1), 9.
- Palchykov, V. A., Zazharskyi, V. V., Brygadyrenko, V. V., Davydenko, P. O., Kulishenko, O. M., Borovik, I. V., Chumak, V., Kryvaya, A., & Boyko, O. O. (2019). Bactericidal, protistocidal, nematocidal properties and chemical composition of ethanol extract of *Punica granatum* peel. *Biosystems Diversity*, 27(3), 300–306.
- Paul, A., & Gerding, J. (1990). Microbiology of the canine and feline eye. *Veterinary Clinics of North America*, 20(3), 615–625.
- Płoneczka-Janeczko, K., Bania, J., Bierowiec, K., Kielbowicz, M., & Kielbowicz, Z. (2017). Bacterial diversity in feline conjunctiva based on 16S rRNA gene sequence analysis: A pilot study. *BioMed Research International*, 2017, 3710404.
- Quitoco, I. M., Ramundo, M. S., Silva-Carvalho, M. C., Souza, R. R., Beltrame, C. O., de Oliveira, T. F., Araújo, R., Del Peloso, P. F., Coelho, L. R., & Figueiredo, A. M. (2013). First report in South America of companion animal colonization by the USA1100 clone of community-acquired methicillin-resistant *Staphylococcus aureus* (ST30) and by the European clone of methicillin-resistant *Staphylococcus pseudintermedius* (ST71). *BMC Research Notes*, 6, 336.
- Rampazzo, S. A., Appino, P., Pregel, A., Tarducci, E., & Biolatti, Z. B. (2008). Prevalence of *Chlamydomphila felis* and Feline Herpesvirus 1 in cats with conjunctivitis in Northern Italy. *Journal of Veterinary Internal Medicine*, 17(6), 799–807.
- Rasigade, J. P. (2018). Catching the evader: Can monoclonal antibodies interfere with *Staphylococcus aureus* immune escape? *Virulence*, 9(1), 1–4.
- Sjödahl-Essén, T., Tidholm, A., Thorén, P., Persson-Wadman, A., Bölske, G., Aspán, A., & Berndtsson, L. T. (2008). Evaluation of different sampling methods and results of real-time PCR for detection of feline herpes virus-1, *Chlamydomphila felis* and *Mycoplasma felis* in cats. *Veterinary Ophthalmology*, 11(6), 375–380.
- Sohn, J. H., Kaplan, H. J., Suk, H. J., Bora, P. S., & Bora, N. S. (2000). Chronic low level complement activation within the eye is controlled by intraocular complement regulatory proteins. *Investigative Ophthalmology and Visual Science*, 41, 3492–3502.
- Spadea, L., Tonti, E., Spatema, A., & Marchegiani, A. (2018). Use of ozone-based eye drops: A series of cases in veterinary and human spontaneous ocular pathologies. *Case Report in Ophthalmology*, 9(2), 287–298.
- Sykes, J. E. (2005). Feline chlamydiosis. *Journal Clinical Techniques in Small Animal Practice*, 20(2), 129–134.
- Towbin, H., Staehlin, T., & Gordon, J. (1979). Electrophoretic transfer of proteins from polyacrylamide gels to nitrocellulose sheets: Procedure and some applications. *Proceedings of the National Academy of Sciences*, 76, 4350–4354.
- Vincze, S., Brandenburg, A. G., Espelage, W., Stamm, I., Wieler, L. H., Kopp, P. A., Lübke-Becker, A., & Walther, B. (2014). Risk factors for MRSA infection in companion animals: Results from a case-control study within Germany. *International Journal of Medical Microbiology*, 304(7), 787–793.
- Weese, S. J., Nichols, J., Jalali, M., & Litster, A. (2015). The oral and conjunctival microbiotas in cats with and without feline immunodeficiency virus infection. *American Journal of Veterinary Research*, 46, 21.
- Wieler, L. H., Ewers, C., Guenther, S., Walther, B., & Lübke-Becker, A. (2011). Methicillin-resistant staphylococci (MRS) and extended-spectrum beta-lactamases (ESBL)-producing Enterobacteriaceae in companion animals: Nosocomial infections as one reason for the rising prevalence of these potential zoonotic pathogens in clinical samples. *International Journal of Medical Microbiology*, 301(8), 635–641.
- Wieliczko, A. K., & Płoneczka-Janeczko, K. (2010). Feline herpesvirus 1 and *Chlamydomphila felis* prevalence in cats with chronic conjunctivitis. *Journal of Veterinary Science*, 13(2), 381–383.
- Worthing, K. A., Brown, J., Gerber, L., Trott, D. J., Abraham, S., & Norris, J. M. (2018). Methicillin-resistant staphylococci amongst veterinary personnel, personnel-owned pets, patients and the hospital environment of two small animal veterinary hospitals. *Veterinary Microbiology*, 223, 79–85.
- Yoong, P., & Pier, G. B. (2010). Antibody-mediated enhancement of community-acquired methicillin-resistant *Staphylococcus aureus* infection. *Proceedings of the National Academy of Sciences of the United States of America*, 107(5), 2241–2246.
- Zazharskyi, V., Davydenko, P., Kulishenko, O., Borovik, I., Brygadyrenko, V., & Zazharska, N. (2019). Antibacterial activity of herbal infusions against *Staphylococcus aureus*, *Staphylococcus epidermidis* and *Pseudomonas aeruginosa* in vitro. *Magyar Allatorvosok Lapja*, 141, 693–704.