

Original researches

Anatomical and histological characteristics of the dromedary eye (*Camelus dromedarius*)

D. E. Rahmoun¹, M. A. Lieshchova², D. E. Gherissi¹, T. Hadjeris¹

¹University of Mohamed Cherif Messaâdia, Souk Ahras, Algeria

²Dnipro State Agrarian and Economic University, Dnipro, Ukraine

Received: 29 April 2020

Revised: 27 May 2020

Accepted: 10 June 2020

University of Mohamed Cherif Messaâdia,
Souk Ahras, 41000, Algérie

Tel.: +213-663-121-367

E-mail: deddine44@hotmail.com

Dnipro State Agrarian and Economic
University, S. Efremov Str. 25, 49600,
Dnipro, Ukraine

Tel.: +8067-256-24-86

E-mail: lieshchova.m.o@dsau.dp.ua

Cite this article: Rahmoun, D. E., Lieshchova, M. A., Gherissi, D. E., & Hadjeris, T. (2020). Anatomical and histological characteristics of the dromedary eye (*Camelus dromedarius*). *Theoretical and Applied Veterinary Medicine*, 8(2), 132–138. doi: 10.32819/2020.82018

Abstract. The anatomy and features of the histological structure of the components of the eye of a one-humped camel were investigated. Ultrasound examinations of the eye, determination of the iridocorneal angle with a gynoscope were carried out on live animals in the clinic after the introduction of eye drops (xylocaine 2%, atropine sulfate 3%). The condition of the eye membranes was determined by histological methods. The studies were carried out on twenty eyeballs from ten clinically healthy adult camels, selected during slaughter in a meat processing enterprise. The anatomical and topographic features of the organ, its membranes and structures, absolute and relative mass, and linear measurements were determined. Thin histological sections of the eye wall were stained with hematoxylin and eosin, impregnated with silver nitrate, followed by examination under a microscope. In a one-humped camel, the eyelashes of both eyelids are very thick and long. The internal architectonics of the eyeball of a one-humped camel is similar to that of other animal species. The lens was found to be a transparent biconvex structure located inside the eyeball just behind the iris. The cornea of the eye occupies almost the entire visible part of the eye. The ciliary body is located behind the iris near the lens. The main functions of the ciliary body are the formation of intraocular fluid (aqueous humor), which fills the front of the eye. The ciliary body contains muscles that enable the eye to focus on objects located at different distances. A feature of the camel's eye is the very open iridocorneal angle. The retina is built up by nerve tissue that lines the back of the eye. The retina perceives light, generates impulses that pass through the optic nerve and are sent to the brain. The histological structure of the membranes of the eye was studied after applying routine methods. It has been established that the eyes are built by various types of tissues, in particular, epithelial (epithelium of the conjunctiva), dense loose connective tissue (the corneal substance itself), loose connective tissue and pigment tissue (choroid) and nervous tissue with a layer of melanocytes and keratinocytes.

Keywords: cornea; ciliary body; lens; eyeball; iris; optic nerve; retina.

Анатомо-гістологічна характеристика оболонок ока одногогорбого верблюда (*Camelus dromedarius*)

Е. Д. Рахмун¹, М. О. Лещова², Д. У. Гхериссі¹, Т. Хадерис¹

¹Університет Сук Ахраса, Сук-Ахрас, Алжир

²Дніпровський державний аграрно-економічний університет, Дніпро, Україна

Анотація. Досліджено анатомію і особливості гістологічної будови складових ока одногогорбого верблюда. Ультразвукові дослідження ока, визначення іридокорнеального кута гіноскопом проводили на живих тваринах в клініці після введення очних крапель (ксилокаїн 2%, атропіна сульфату 3%). Стан оболонок ока визначали гістологічними методами. Дослідження проведені на двадцяти очних яблуках від десяти клінічно здорових дорослих верблюдів, відібраних при заборі в мовах м'ясопереробного підприємства. Визначали анатомо-топографічні особливості органа, його оболонок та структур, абсолютну і відносну маси, лінійні проміри. Тонкі гістологічні зрізи стінки ока забарвлювали гематоксилином і еозином, імпрегнували азотнокислим сріблом з подальшим вивченням під мікроскопом. У одногогорбого верблюда віі обох повік дуже густі та довгі. Внутрішня аргітектоніка очного яблука одногогорбого верблюда аналогічна такій у інших видів тварин. Встановили, що кришталик являє собою прозору двоопуклу структуру, розміщену всередині очного яблука безпосередньо за райдужкою. Рогівка ока займає майже всю видиму частину ока. Війкове тіло знаходиться позаду райдужки біла кришталика. Основні функції війкового тіла – це утворення внутрішньоочної рідини (водянистої вологи), яка заповнює передню частину ока. До складу війкового тіла входять м'язи, завдяки яким око може фокусуватися на об'єктах, розміщених на різній відстані. Особливістю ока верблюда являється дуже відкритий іридокорнеальний кут. Сітківка побудована нервовою тканиною, що вистеляє задню поверхню ока. Сітківка сприймає світло, генерує імпульси, які проходять через зоровий нерв і прямують в головний мозок. Гістологічна структура оболонок ока вивчена після застосування рутинних методів. Встановлено, що ока побудоване різними типами тканин, зокрема епітеліальної (епітелій кон'юнктиви), щільної неоформленої сполучної тканини (власне речовина рогівки), пухкої сполучної тканини і пігментної тканини (судинна оболонка) і нервової тканини з шаром меланоцитів і кератиноцитів.

Ключові слова: рогівка; війкове тіло; кришталик; очне яблуко; райдужка; радужка; зоровий нерв; сітківка.

Introduction

The dromedary (*Camelus dromedarius*) is the largest mammal perfectly fitted to survive and breed under extreme arid conditions despite prolonged droughts, drastic fluctuations in ambient temperatures (frost and heat waves) and food shortages (Bouâouda et al., 2014). Some of its morpho-functional peculiarities allow him to fight against desertification and participate in preserving the ecological balance of the Saharan regions. The need for vision is not the same according to the species, in particular according to the environment in which it lives, the speed with which it moves the food which it must acquire and the vigilance which it must show. Therefore, the ocular performance depends in the degree of perfection of the image design on the retina with respect to the object which sends light rays on the eyes to appreciate its brightness, shape, dimensions, position in space and possibly colors and movements. The dromedary has large eyes which have thick, double-layered eyelashes and bushy eyebrows and they have sharp vision. Their orbits are circular, equidistant, completely osseous and markedly projecting laterally (Noor et al., 2018). The camel eyes are protected by prominent supra-orbital ridges and have three eyelids. They move from side to side rather than up and down. The lenses of their eyes contain crystallin, which constitutes 8 to 13% of the protein present there (Garland et al., 1991).

In general, the eye, or eyeball, is a hollow structure with a generally spherical shape after (Bourges et al. 2007). It consists of different tunics, a lens and liquids. The outermost coat is the sclera, which is made up of dense, poor vascular connective tissue and thus fulfills a protective role for the eye. On the anterior side, this sclera is replaced by the transparent cornea (Coile et al., 1988). It is this cornea which allows the penetration of light rays into the eyeball. It is rich in nociceptive fibers: contact with an object induces blinking and tear secretion (Thomasy et al., 2016), thus protecting the eye from contact and bacterial attack. More internal than these essentially protective envelopes are the vascular coat formed of three parts, according to Rahi et al. (1980), the choroid is a highly vascularized membrane and pigmented in brown by melanocytes. The ciliary body and the iris, according to the data of Ofri et al. (2008), essentially formed of smooth muscles which, thanks to their contractions, modify the shape of the lens and thus allow accommodation. The iris is the colored and visible part of the eye, composed of smooth muscles, it allows controlling the size of the pupil (Jia et al., 2017) and therefore the light rays entering the eyeball, it plays a role diaphragm.

The innermost tunic is the retina, which is made up of two layers. The outer pigment layer prevents light from diffusing into the eye, the inner layer is a nervous structure made up of numerous photoreceptors which are the cones and rods and cells which process and convey visual information to the brain. This structure is part of the central nervous system. Efferent nerve fibers exit the eye through the optic nerve (Verra et al., 2020). At this exit point, the retina is naturally interrupted, it is the blind spot (Abarca et al., 2020). Near this blind spot is the yellow spot which is the fovea, which is the point of the retina with the best visual acuity whose light rays arrive directly, with the least interference, and this is where the density of photoreceptors is the most important. The lens is a thin, elastic capsule made up of anucleated cells and specific fibers, according to researchers from (Abdo et al., 2014), it plays the role of a biconvex lens. The lens and its suspensory ligament divide the eyeball into two chambers. The anterior chamber is filled with a liquid, the aqueous humor, which is continuously renewed. The posterior chamber is filled with a transparent gelatinous substance, the vitreous body or vitreous humor. The vitreous body contributes to intraocular pressure and thus to the shape of the eye.

Our investigation consists on the study of the vision organ 'the eye' of particular mammal species living on one of the most arid condition of the globe; the dromedary camel (*Camelus Dromedarius*)

from the local Sahraoui breed of Algerian south east region. Based on the already exploited data, a deep morpho-histological investigation was planned to deeply explore this organ for this species.

Materials and methods

The study was carried out on twenty carcass eyeballs from ten clinically healthy adult dromedaries from southern Algeria, weighing between 350 and 400 kg. The heads of the hanging animals, the ocular region is then prepared, the anatomo-topographic characteristics of each globe have been determined. The eyelid incision is started with a scalpel, the skin and the conjunctiva incised 1 cm from the edge of the eyelashes.

The circular incision must then continue in depth, ensuring that it remains close to the orbit. The medial and lateral ligaments are cut, as well as each of the straight muscles at their point of insertion. Traction was exerted on the eyeball in order to be able to incise the muscles using scissors. The optic nerve is tightened and ligated. The orbital cone is then sectioned and the eyeball removed and placed in clean compresses.

The mass was taken with an electronic balance and the measurement of the length and the circumference of the organs with a measuring tape.

Ocular ultrasound and examination of the iridocorneal angle were carried out at the institute's clinic on live dromedaries, after having instilled ophthalmic xylocaine eye drops at 2% then drops of atropine sulfate a 3% to dilate the pupil and allow examination of the back of the eye.

A DP-10 Mindray 10-12 MHz convex probe in B mode, with a portable and compact ultrasound system, allowed us to achieve a focus around 23 mm which is the average axial length of the dromedary's eyeball and a global visualization of the eyeball, we could see the posterior segment. A layer of conduction gel has been put on the eye of the dromedary, according to the techniques cited by the authors (Guyomard et al., 2008), the ultrasound probe is placed and a careful adjustment has been made to clearly visualize the image on the device screen, the photos are removed and analyzed.

The examination of the iridocorneal angle of the eye on the same animals was carried out with a Sanotek Volk lens, contact lens for examination with a slit lamp according to the technique of (Chaudieu et al., 2019). The microphotography was carried out with a Bresser LCD 8.9 cm (3.5"), 50-500x, 2000 (digital) optical microscope, which allowed us to visualize the different areas of the different fragments.

The histological studies were carried out in the histology laboratory of the Institute of Agronomic and Veterinary Sciences Toura Souk Ahras, Algeria. The eyeballs have undergone meticulous preparation which consists in removing the adipose tissue which envelops these organs; this stage requires the use of a scalpel. The absolute weight of the organs adjusted using an electronic scale «Tehniplot-WTW», up to 0.002 mg. Likewise, the relative mass of the organs relative to the weight of the animal body was calculated. The measurements (length, width) of each eyeball were determined using a measuring tape with a division value of 1 mm.

The eyeballs were carefully dissected using a dissecting microscope to study the eyelids, the lacrimal glands, the eye layers (fibrous, vascular and nerve) and the eye muscles, the parts obtained are immersed in a 10% formalin solution for a fixation of 24 to 48 hours for possible histological research.

After washing the fragments with running water and then dehydrating with ethyl alcohol to an increasing concentration, the fragments of the organs were poured into paraffin. The microtome section allows us to obtain thin sections of 5 microns which will be stained with Hematoxylin & Eosin and this to highlight the morphology and histology of the organs as staining techniques cited by the authors (Gherissi et al., 2017; Eddine et al., 2020; Fares et al., 2020).

Other histological sections of the eye fragments, of 15 microns, were subjected to silver nitrate impregnations according to the technique cited in the article by (Gibbings & Jakubzick, 2018)

Results

Macroscopic examination revealed that the dromedary's eyeballs were located almost at equal distance between the premaxilla and nuchal crest. The frontal bone formed the roof of the orbit and part of the medial wall. The zygomatic process of the frontal bone extended laterally and formed a large part of the roof and the lateral wall of the bone orbit.

It has been noted that the zygomatic bone forms most of the rostral and ventral edge of the orbital edge and the rostro-ventral part of the wall of the orbit, circular in shape, of symmetrical movement and not diploid.

It has also been noted that the orbital cornea, which was a light blue area formed by a thin layer modified skin with little hair, surrounded the eyelids. The eyelids and conjunctiva are in upper and lower positions that keep the eye, they are quite thick and seemed rolled or thrown in transverse mounds seen in the living animal. A third eyelid was also observed in the medial canthus. Long eyelashes were also found in both eyelids, and the eyelashes on the upper eyelid were coarse and longer than those attached to the lower eyelid. The longest eyelashes of the upper eyelid were in its middle parts, while the longest eyelashes of the lower eyelid were in its middle third.

The conjunctiva was attached to the eyelids and there was a pigmented junction of the conjunctiva and eyelids at the lateral angle, but the median angle was devoid of pigment. The palpebral fissure was elliptical in shape but wider towards the medial angle. The conjunctiva that covers the third eyelid forms a fold covering an underlying T-shaped cartilage.

The ocular muscles observed included the dorsal, ventral, and medial and lateral muscle fibers, the dorsal and ventral oblique, and the retractor bulb. At the ventral oblique, it was noticed that the muscle was inserted in the sclera between the ventral and lateral caudal muscles. The oblique dorsal muscle is inserted into the sclera. The origin of the retractor bulb muscle was close to the optic foramen and its insertion was on the posterior surface of the globe.

The sclera appears as a shell of fibrous connective tissue, dense, opaque and vascularized, open in front at the level of the cornea, with which it continues, and extended behind by the dura mater of the optic nerve.

The cord-shaped optic nerve, which emerged from the ventrolateral aspect of the globe, the optic disc was a whitish patch circular to the caudo-ventral part of the globe from which the optic nerve originated. Two main divisions of the nerve were observed:

the upper division and the lower division which was larger. The study of the mass of the eye of the dromedary revealed the data mentioned in the table below.

A deep examination of the tunics of the eyeball revealed to us that there were three layers of the dromedary were studied in longitudinal sections. A fibrous layer was detected which consisted of a large whitish sclera and a small transparent central cornea. The sclera, penetrated caudo-ventrally by the optic nerve, was thin at the points of attachment of the rectal muscles. He showed black pigmentation along the corneoscleral junction. The cornea was more strongly curved than the sclera and it was transparent although some pigmentation, in particular towards the corneal-sclera junction.

Regarding the vascular layer, it was composed of the choroid, the ciliary body and the iris. The choroid had a dark, highly pigmented outer layer and an inner vascular layer. The ciliary body was located in the caudal position relative to the lens and was composed of radials arranged ciliary processes, which included the pupil, and grooves to which the zonule or the suspensor ligament of the lens was attached. The iris was interposed between the cranial cornea and the caudal lens where it was attached to the anterior margin of the ciliary body. The cornea morphometry was performed and the data mentioned below were found.

The nerve coat or retina was gray in color and formed the entire lining of the eyeball. It was limited cranial by the iris and caudal by the origin of the optic nerve.

For the lens, we noticed that it was located caudally to the iris, biconvex in shape and was attached to the ciliary body. the use of ultrasound allowed us to the different layers of the eye. The lens appears as a biconvex structure, transparent and soft, connected to the ciliary bodies. The lens is a transparent, non-vascular epithelial mass. The lens is connected by the suspensory ligament of the lens to the ciliary body. The ciliary muscles contained in the connective stroma t innervated by the parasympathetic, can thus modify the shape of the lens and allow accommodation from a distance (Fig. 1).

The ultrasound image in mode A showed us a wall of the sclera, extended anteriorly by the cornea, the uvea appears as a membrane represented by the choroid behind which is extended forward by the ciliary body and the iris. The retina, membrane seems to appear as anechoic transparent media on an axial section.

In mode B, the anterior segment includes the cornea, the anterior chamber, the lens, the iris and the ciliary body, which is hyperechoic while the vitreous is anechoic. The lens, an anechoic biconvex lens is limited by the capsules, the iris appears very echogenic. The anterior surface (epithelium) and the posterior surface (endothelium) of the center of the cornea appear as hyper echoic lines. At the periphery, the cornea is not materialized due to the diffraction of the ultrasound. The anterior chamber filled with aqueous humor is anechoic (or crystalloid) anterior and posterior

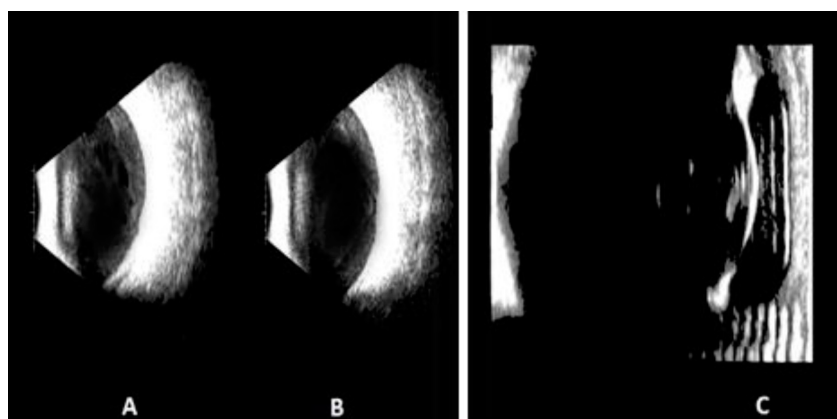


Fig. 1. Dromedary eye ultrasound: A and B – reverse transmission mode, C – direct transmission mode.

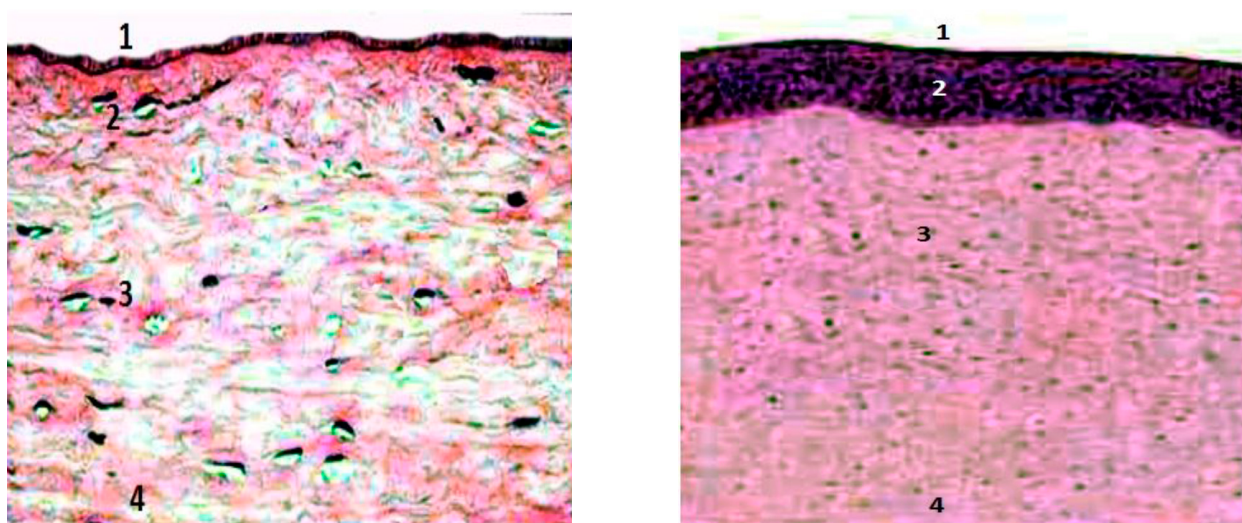


Fig. 2. Histological section of the cornea of the dromedary eye stained with Hematoxylin & Eosin, $\times 40$. 1 – corneal squamous epithelium, 2 – membrane of Bowman's layer, 3 – stroma, 4 – Descemet's membrane.

echogenic. The anterior capsule protrudes discreetly at the level of the pupil relative to the irian plane, because the ultrasound beam is perpendicular to it and the ciliary body moderately echogenic. Regarding the aqueous humor is formed of transparent liquid which fills the space between the cornea and the lens. The glazed body is formed of transparent liquid.

After staining with Hematoxylin and eosin, the cornea appears as a thin, transparent, completely non-vascularized membrane, consisting of several cellular layers of stratified squamous epithelium, non-keratinizing, the corneal stroma, appears dense and thick, rich in fibroblasts and in collagen, also we noticed a layer of simple squamous epithelium. No blood or lymphatic vessels were detected (Fig. 2).

So we deduced that the cornea is a blade of dense connective tissue, oriented, transparent and avascular, coated on each of its faces by an epithelium. The cornea does not contain blood vessels. Its nutrition is ensured by imbibitions from the aqueous humor. The anterior epithelium, a stratified non-keratinized epithelium, rests by its basal surface on a basement membrane distinct from the Bowman's membrane. Its apical surface, lined with micro pleats,

retains an aqueous film of tears permanently moistening the cornea. It has been found upon examination under an optical microscope that the cornea attributes three main components to this tissue: the epithelium, the stroma, and the endothelium, it is made up of three main layers: epithelium, stroma and endothelium.

The posterior epithelium (often called the endothelium), simple squamous, rests on a thickened basement membrane which is none other than Descemet membrane. The dense collagen stroma occupies 90% of the cornea between the 2 epithelia. It is limited in front by the Bowman membrane and behind by the Descemet membrane. The epithelium and the stroma are separated by a thin acellular layer (Bowman layer), the thickness of the tear film (on the order of a micron) is negligible compared to that of the epithelium. The stroma represents approximately 90% of the thickness of the corneal wall, transparency, biomechanical resistance and optical power.

The histological section of the anterior part revealed the structure of the choroid, located between the sclera and the retina, formed of loose connective tissue, very vascular, rich in much pigmented melanocytes.

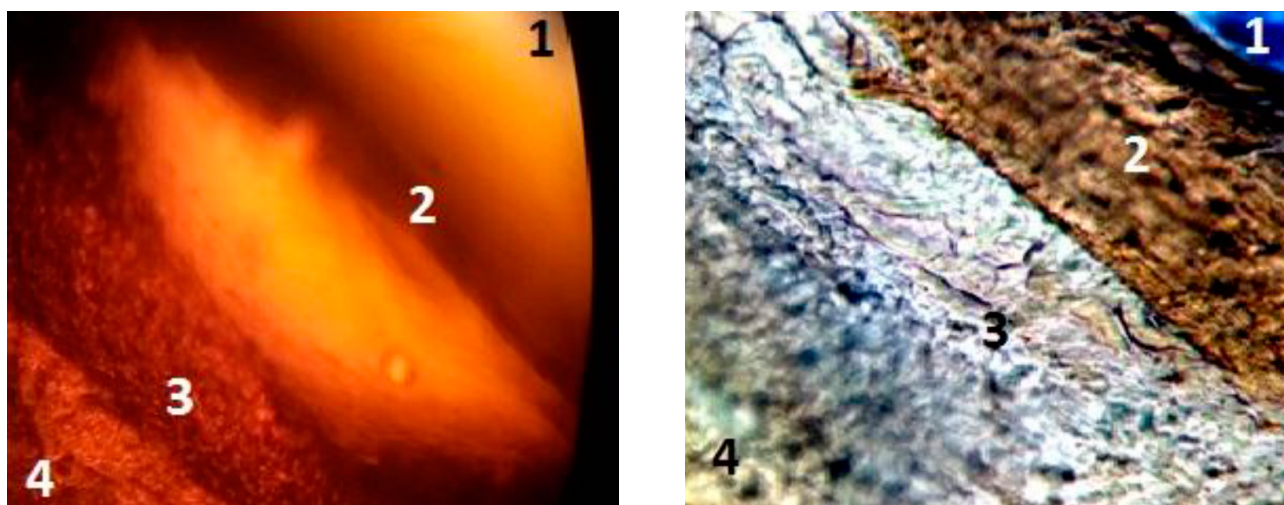


Fig. 3. Examination of the iridocornean angle and impregnation of the fragment obtained with silver nitrate from the dromedary. 1 – aqueous humor, 2 – shlemm canal, 3 – trabeculum, 4 – ciliary body.



Fig. 4. Histological section of the lens of the dromedary's eye impregnated with silver nitrate. The fibers in the shape of a crystal concentrated at the periphery.

On the other hand, it has been detected that the choroid is a thin layer of loose connective tissue containing many blood vessels and nerves as well as melanocytes which give it its characteristic color. From surface to depth, we find the layer of vessels, which contains very many arteries and veins dependent on the ciliary vessel system, also the choriocapillary layer is characterized by the presence of an important capillary network depending on the vessels of the layer previous, a thin layer of collagen and elastic micro fibrils covered on one side by the basement membrane of the capillaries of the choriocapillary layer and on the other by the basement membrane of the pigment epithelium of the retina. The ciliary bodies were found in a circular form of loose connective tissue and capillaries with small, no pigmented epithelial expansions.

Regarding the iris, it appears on examination that it has an anterior surface bordered by a discontinuous layer of stromal cells; no border between the lower chamber and the iris whose stroma contains fibroblasts, collagen, nerve fibers, smooth muscles, melanocytes and blood vessels; the darker colored pigment which consists of long filaments.

The cut examination made of the part corresponding to the iris showed us that it is formed of connective tissue, much vascularized rich in melanocytes, and its anterior face: irregular, bordered by fibroblastic cells and its posterior face is formed of pigment cells. The silver nitrate impregnation revealed the presence of abundant black melanin.

For the corneal irido canal or Schlemm canal, it appears well dilated on the histological section made and stained with silver nitrate (Fig. 3).

The examination of the iridocornean angle showed us that it is very open, the motility of the globe is weighable at the pressure of the fingers, we could not take the intraocular pressure because the standards of the scale of Shultz is not compatible with that of the dromedary.

The ciliary epithelium has a pigmented outer part and no pigmented inner part; the unpigmented portion produces zonular ligaments and a basement membrane. The ciliary muscle and arranged when the muscle contracts with parasympathetic stimulation, the tension is decreased on the support lens of the zonular fibers and the lens becomes more spherical due to the native elasticity of the lens capsule, the zonular ligaments form support for the collagen unit.

On examination under the microscope of histological sections of the iridocornean angle, the corneal stroma is extended by the opaque sclera connective tissue while the anterior epithelium is continued by the epithelium of the bulbar conjunctiva, the posterior corneal

epithelium is reflected at the iridocornean angle and continues by lining the anterior surface of the iris, the spaces of the connective stroma of this area drain the aqueous humor from the anterior chamber towards the Schlemm canal located in the sclera, on the other hand in its anterior part, the choroid constitutes the iris and the ciliary processes, the epithelium which lines the anterior surface is simple cubic (reflected corneal posterior epithelium) while the posterior surface of the iris and the ciliary processes are covered by an epithelium pigmented laminate of the blind retina, the iris axis has two groups of smooth muscles.

The ciliary processes are very vascular and covered by the bistrified epithelium of the blind retina. The blood capillaries are fenestrated there, they secrete the aqueous humor, absorbed at the level of the iridocornean angle, the ciliary processes maintain the lens by a system of filaments of the zonula.

Regarding the lens, its staining on a slide has shown us that it is formed of a homogeneous fibrous capsule which is the crystalloid. The antero-posterior layout epithelial cells, packed against each other (Fig. 4).

The observation of the blades made on the dromedary's retina showed us that it is made up of an outer pigmentary layer made up of a simple epithelium made of squamous cells and an inner neurosensory cell made up of neurons.

The staining with silver nitrate of the section in the region of the lacrimal gland showed us a glandular structure of epithelial type, of juxtglomerular positioning with very intense activity.

Discussion

In the present study, the orbit of the dromedary appears completely bony, circular and equidistant, this is confirmed by the conclusions of (Fowler et al. 1988) who mentioned that the orbit is located at the border of the skull between the skull and the face. The presence of a colored orbital crown surrounding the eyelids was reported for the first time. The authors Petit et al. (2019) described the third eyelid of the dromedary as a large conjunctival semi-lunar fold extending up to 3 cm from the medial canthus on the anterior surface of the eyeball. In the current investigation, the third eyelid has formed a fold covering an underlying T-shaped cartilage. In dromedaries the third eyelid is located on the rostromedial side of the eyeball and it is quadrilateral in outline in the dromedary (Noor et al., 2018) in the same species. In domestic mammals, the superficial part of the third eyelid has dark pigmentation with a free margin, according to the researchers (Micheau et al., 2016).

In addition, Abarca et al. (2020) mentioned that another dark

pigmentation appears at the line of reflection of the conjunctiva on the superficial gland of the third eyelid, especially in old camels.

Current results have shown a pigmented junction of the conjunctiva and eyelids at the lateral angle. According to Lossi et al. (2016), there were dark pigmented areas on several horizontal lines on the caudal half of the conjunctiva that represented subconjunctival lymph nodules.

Unlike other domestic animals (Banks et al., 2015), the present study has shown that the eyelashes of the two eyelids in dromedaries are numerous and extremely long. In addition, a tuft of long eyelashes was observed dorsal to the medial canthus. It was also found that the median margin of the camel's eyelids has a triangular hairy area. The eyelash lashes and the tuft were probably protective mechanisms against sunlight, dust, foreign bodies and insects, moreover Malhotra et al. (2011) suggests that the long, strong and densely lashed eyelashes Dromedary eyelids are important in the dry, sandy environment.

According to our research, we deduced that the lacrimal gland was lobulated and it included dorsal and ventral parts. The periorbita formed a two-layer fascial pocket around the gland, which occupied the craniodorsal part of the eyeball just medial to the zygomatic process of the frontal bone. The position and shape of the lacrimal gland were similar to those described by the authors (Mohammad et al., 2008), on the other hand in our research, we did not detect any punctuation was observed, this confirms the report of Rahi et al. (1980) on the dromedary.

The number and distribution of ocular muscles currently reported in dromedaries are similar to those described by (Noor et al., 2018). The present study confirms the conclusions of according to which the motor nervous supply to the muscles of the eyeball comes from the oculomotor, trochlear and abducent nerves. The weight and volume of the eyeball with and without periorbital have been described for the first time.

The internal architecture of the eyeball in this study is similar to that of other domestic animals (Abdo et al. 2017). It contained three layers: fibrous, vascular layer, layer and nerve layer (retina). However, in the present investigation, the sclera formed most of the fibrous layer. This is in agreement with the conclusions of Tavousi et al. (2013), who stated that the sclera made up 85%. In addition, in this study, the corneoscleral junction is strongly pigmented in black. This and the strong pigmentation of the choroid may absorb harmful rays (ultraviolet).

In the present study, the weight of the eyeball with periorbita was approximately 41.9 g and without periorbita was approximately 21.2 g; its volume with periorbita was approximately 4.55 cm³ and without periorbita was approximately 2.2 cm³. The different measurements of the right and left eye in this study showed that there were no significant differences. The dromedary's eyeball also weighs approximately 36.2 g and to measure approximately 3.7 cm in length and approximately 4.1 cm in width, the researchers Abdo et al. (2014), indicated that the dimensions of the dromedary's eyeball were 4.5 cm in length and 4.0 cm in width (Cholkar et al., 2013), they state that the dimensions of the dromedary's eyeball are 4.5 cm long and 4.0 cm wide. In addition, Rahi et al. (1980) stated that the dromedary's eyeball is approximately 3.5 cm long and 3.1 cm wide, the cornea is approximately 2.5 cm long and 1.7 cm wide. The controversy in these reported measures could be due to differences in age and breed of the animals studied.

In our results, we elucidated that the main body of the sclera in other animals resembles the dermis of the skin which includes a large amount of irregular connective tissue which corresponds to the results of (Bess et al., 2016).

In most animals, the outer layer of sclera or epiclerium is also made up of very vascular connective tissue loss and containing neural fibers (Eurell et al., 2013). The dromedary has the longest dorsal and ventral plateau, followed by the donkey, buffalo and cow.

On the other hand, the medial and lateral shelves are the longest for the donkey and the smallest for the dromedary according to (Kassab et al., 2011). The epithelial tissue of the cornea in dogs, the authors describe that the cats and birds consists of a layer of basal cells with two or three layers of polyhedral cells (wing) or parts and 2 or 3 layers of non-keratinized squamous cells (Micheau et al., 2016).

In most animals, the corneal stroma represents 90% of the thickness of the cornea, it is of the ligament type, consisting of transparent strips of dense connective tissue (Cholkar et al., 2013). In some animals, at the level of the fine structure, the membrane of the descemet is made up of three regions: an anterior non-bandaged area, an anterior bandaged area and a posterior non-bandaged area has been reported (Kassab et al., 2011).

Descemet's membrane is a homogeneous acellular membrane 10 to 15 µm thick in dogs and up to 30 µm thick in horses (Bourges et al., 2007).

This layer is a true basement membrane formed by an endothelium membrane (Vézina et al., 2012). In other animals, the corneal endothelium contains a layer of cuboid or polygonal cells and has covered the posterior surface of the cornea (Koizumi et al., 2012). In some animals, the existence of hexagonal cells in this layer has been reported by (Abdo et al., 2014). In anatomy, with the exception of a few differences, the camel's cornea and sclera are similar to those of other ungulates. Except for a few small differences in the Bowman layer and Descemet's membrane, it is similar to the fibrous coat of other animals.

Conclusion

The present study found several variations in the overall anatomy of the dromedary's eye compared to other domestic animals, these variations could be structural modifications adapted to the difficult desert conditions. The dromedary's eyeball appears like a sphere, made up of three shells. The outer fibrous membrane consists of an opaque sclera, which passes in front of the cornea. On the outside, the sclera is covered with a thin transparent mucosa, the conjunctiva. The middle membrane is called the vascular. From its name, it is clear that it contains many vessels that supply the eyeball. It forms in particular the ciliary body and the iris. The inner lining of the eye is the retina. The eye also has appendages, in particular the eyelids and the lacrimal organs. Six muscles control eye movement - four straight and two oblique.

In its structure and its ocular functions, it can be compared to an optical system, for example a camera. The image on the retina is formed as a result of the refraction of light rays in the system of lenses located in the eye (cornea and lens) (lens analog). The front surface of the cornea is covered with epithelium, which has the ability to regenerate (repair) when damaged. The stroma, made up of collagen fibers, is deeper and the inside of the cornea is covered with a layer of endothelial cells. The cornea is a lens that represents and the most solid lens of the optical system of the eye. The so-called anterior chamber of the eye, filled with fluid, the space between the inner surface of the cornea and the iris which is a diaphragm with a hole in the center of the pupil

The periphery of the cornea around the entire circumference connects practically to the iris, forming what is called the angle of the anterior chamber, through the anatomical elements including (the Schlemm canal, the trabecula and other formations, collectively called ocular drainage pathways), the flow of fluid constantly flowing through the eye into the venous system. There is a lens behind the iris - another lens that refracts light. The optical power of this lens is lower than that of the cornea. The lens around the circumference has ligaments similar to filaments, which connect to the ciliary muscles located in the wall of the eye. These muscles can contract and relax. Depending on that, the lens in its structure is similar to a grape having a bone - it has a shell, a capsule bag, a denser substance,

the core and a less dense substance, masses of lentils. In young dromedaries, the nucleus of the lens is soft, however, in adults, it becomes denser. The capsule of the front lens faces the iris, the rear capsule is towards the vitreous and the ligaments serve as a border between them. Such a detailed description of the anatomy of the lens will give us the opportunity to understand how the cataract is removed - a cloudy lens, as well as how an artificial lens is implanted in the eye. Around the lens, around its entire circumference, there is a ciliary body, which is part of the choroid. It has processes that produce intraocular fluid. This fluid through the pupil enters the anterior chamber of the eye and through the angle of the anterior chamber is eliminated in the venous system of the eye. The balance between the production and the flow of this fluid is very important. Behind the lens is the vitreous, which occupies most of the eye and gives it shape. It has no other function, but the light practically does not refract. It has a gelatinous structure in most cases, but sometimes it can liquefy. On the other hand, densities zones can appear there in the form of threads or tufts. In some places, the vitreous is tightly welded to the retina, so that when joints form, the vitreous can pull the retina on itself, sometimes causing it to come off. Millions of small photoreceptor retinal cells convert light energy into nerve impulse energy and send it to the brain.

References

- Abdo, M., Hosaka, Y. Z., Erasha, A., Nada, M., Ali, S., & Uehara, M. (2013). Prenatal development of the eye tunics in the dromedary camel (*Camelus dromedarius*). *Anatomia, Histologia, Embryologia*, 43(4), 257–264.
- Banks, M. S., Sprague, W. W., Schmoll, J., Parnell, J. A. Q., & Love, G. D. (2015). Why do animal eyes have pupils of different shapes? *Science Advances*, 1(7), e1500391.
- Bess, S., & Line, B. (2016). Embryology and anatomy: spine/spinal cord. *The Growing Spine*, 3–13.
- Bouâouda, H., Achâaban, M. R., Ouassat, M., Oukassou, M., Piro, M., Challet, E., El Allali, K., & Pévet, P. (2014). Daily regulation of body temperature rhythm in the camel (*Camelus dromedarius*) exposed to experimental desert conditions. *Physiological Reports*, 2(9), e12151.
- Bourges-Abella, N., Raymond-Letron, I., Diquelou, A., Guillot, E., Regnier, A., & Trumel, C. (2007). Comparison of cytologic and histologic evaluations of the conjunctiva in the normal equine eye. *Veterinary Ophthalmology*, 10(1), 12–18.
- Chaudieu, G., & Benard, G. (2019). Intérêt et valeur prédictive de la recherche des anomalies de l'angle irido-cornéen : renseignements fournis par l'examen gonioscopique de 4309 chiens (1998–2018). *Revue Vétérinaire Clinique*, 54(1), 3–21.
- Cholkar, K., Dasari, S. R., Pal, D., & Mitra, A. K. (2013). Eye: anatomy, physiology and barriers to drug delivery. *Ocular Transporters and Receptors*, 1–36.
- Coile, D. C., & O'Keefe, L. P. (1988). Schematic eyes for domestic animals. *Ophthalmic and Physiological Optics*, 8(2), 215–219.
- Eddine, R. D., Amine, F. M., Manel, H., Khaoula, M., & Lieshchova, M. (2020). Morpho-histological study of spleen ontogenesis in lambs during antenatal and postnatal period. *Journal of World's Poultry Research*, 10(1), 12–16.
- Fares, M., Rahmoun, D., & Lieshchova, M. (2020). Histological study of eyelid in Algerian locale bovine. *Ukrainian Journal of Veterinary and Agricultural Sciences*, 3(2), 60–63.
- Fowler, M. E., Smuts, M. M. S., & Bezuidenhout, A. J. (1988). Anatomy of the Dromedary. *The Journal of Zoo Animal Medicine*, 19(3), 136.
- Garland, D., Rao, P. V., Corso, A. D., Mura, U., & Zigler, J. S. (1991). ζ -Crystallin is a major protein in the lens of *Camelus dromedarius*. *Archives of Biochemistry and Biophysics*, 285(1), 134–136.
- Gherissi, D. E., Afri-Bouzebda, F., & Bouzebda, Z. (2017). Seasonal changes in the testicular morphology and interstitial tissue histomorphometry of Sahraoui camel under Algerian extreme arid conditions. *Biological Rhythm Research*, 49(2), 291–301.
- Gibbings, S. L., & Jakubzick, C. V. (2018). Isolation and characterization of mononuclear phagocytes in the mouse lung and lymph nodes. *Lung Innate Immunity and Inflammation*, 33–44.
- Guyomard, J.-L., Rosolen, S. G., Paques, M., Delyfer, M.-N., Simonutti, M., Tessier, Y., Sahel, J. A., Legargasson, J.-F., & Picaud, S. (2008). A low-cost and simple imaging technique of the anterior and posterior segments: eye fundus, ciliary bodies, iridocorneal angle. *Investigative Ophthalmology & Visual Science*, 49(11), 5168.
- Jia, C., Zhang, F., Zhu, Y., Qi, X., & Wang, Y. (2017). Public data mining plus domestic experimental study defined involvement of the old-yet-uncharacterized gene matrix-remodeling associated 7 (MXRA7) in physiopathology of the eye. *Gene*, 632, 43–49.
- Kassab, A. (2011). Ultrasonographic and macroscopic anatomy of the enucleated eyes of the buffalo (*Bos bubalis*) and the one-humped camel (*Camelus dromedarius*) of different ages. *Anatomia, Histologia, Embryologia*, 41(1), 7–11.
- Koizumi, N., Okumura, N., & Kinoshita, S. (2012). Development of new therapeutic modalities for corneal endothelial disease focused on the proliferation of corneal endothelial cells using animal models. *Experimental Eye Research*, 95(1), 60–67.
- Lossi, L., D'Angelo, L., De Girolamo, P., & Merighi, A. (2016). Anatomical features for an adequate choice of experimental animal model in biomedicine: II. Small laboratory rodents, rabbit, and pig. *Annals of Anatomy - Anatomischer Anzeiger*, 204, 11–28.
- Malhotra, A., Minja, F. J., Crum, A., & Burrowes, D. (2011). Ocular anatomy and cross-sectional imaging of the eye. *Seminars in Ultrasound, CT and MRI*, 32(1), 2–13.
- Micheau, A., & Hoa, D. (2016). Dog - General anatomy (Illustrations). *Vet-Anatomy*.
- Mohammad, A. A. (2008). Anatomical characteristics of dorsal lacrimal gland in one humped camel (*Camelus dromedarius*). *Journal of Biological Sciences*, 8(6), 1104–1106.
- Noor, N. A., & El-bably, S. H. (2018). Anatomical studies on the arterial supply of the eye in the one-humped camel (*Camelus dromedarius*). *International Journal of Anatomy and Research*, 6(1.3), 5057–5063.
- Ofri, R. (2008). Retina. *Slatter's Fundamentals of Veterinary Ophthalmology*, 285–317.
- Petit, L., & Pouget, P. (2019). The comparative anatomy of frontal eye fields in primates. *Cortex*, 118, 51–64.
- Rahi, A. H. S., Sheikh, H., & Morgan, G. (1980). Histology of the camel eye. *Cells Tissues Organs*, 106(3), 345–350.
- Tavousi, H., Saadatlou, M. A. E., & Keyhanmanesh, R. (2013). A study of the histogenesis of sheep fetus iris. *Kafkas Universitesi Veteriner Fakultesi Dergisi*.
- Thomas, S. M., Eaton, J. S., Timberlake, M. J., Miller, P. E., Matsumoto, S., & Murphy, C. J. (2016). Species differences in the geometry of the anterior segment differentially affect anterior chamber cell scoring systems in laboratory animals. *Journal of Ocular Pharmacology and Therapeutics*, 32(1), 28–37.
- Verra, D. M., Sajdak, B. S., Merriman, D. K., & Hicks, D. (2020). Diurnal rodents as pertinent animal models of human retinal physiology and pathology. *Progress in Retinal and Eye Research*, 74, 100776.
- Vézina, M. (2012). Comparative ocular anatomy in commonly used laboratory animals. *Molecular and Integrative Toxicology*, 1–21.